

Case performed by Dr. Feriduni – 3144 FU in 1 procedure

FUE performed on a 45-year old patient with

- NW V
- Donor density of 80 FU/cm² occipital, 80 FU/cm² parietal, 80 FU/cm² temporal
- Hair diameter of ~ 52-56 microns

Treatment plan

Follicular Unit Extraction to attain an aesthetic reconstruction of the hairline and the crown area.

Performed procedure

FUE (October 25, 2021)

Follicular Unit Extraction with 3144 FU:

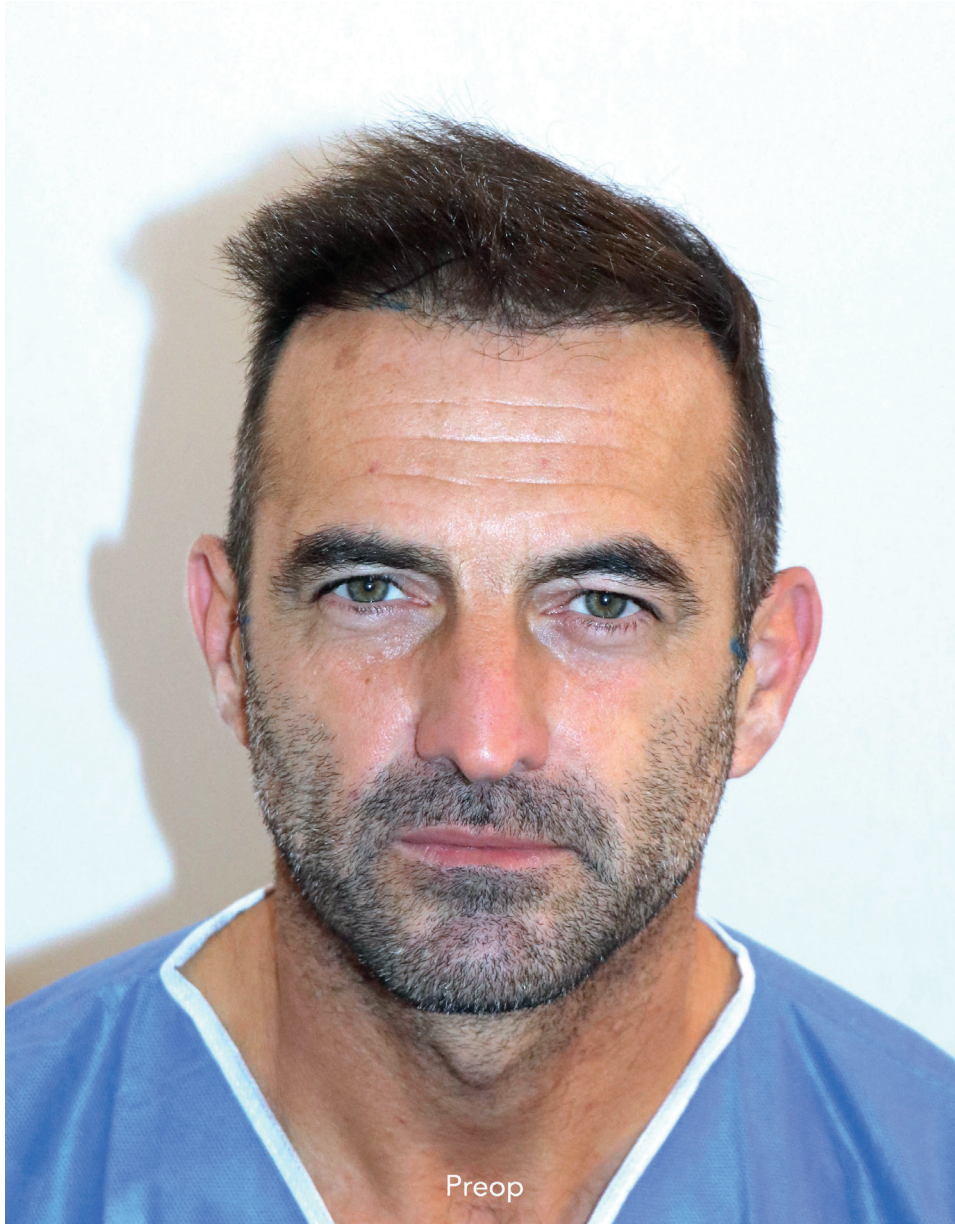- * 398 single hair FU
- * 2060 double hair FU
- * 686 triple hair FU

HGI: 2,1

Parallel incisions in custom-sized blades technique (Cutting Edge blades of 0,8-1,0 mm).
Extraction performed by WAW-system with a 0.85 mm serrated trumpet punch.

No microscopic preparation of the follicular unit grafts.

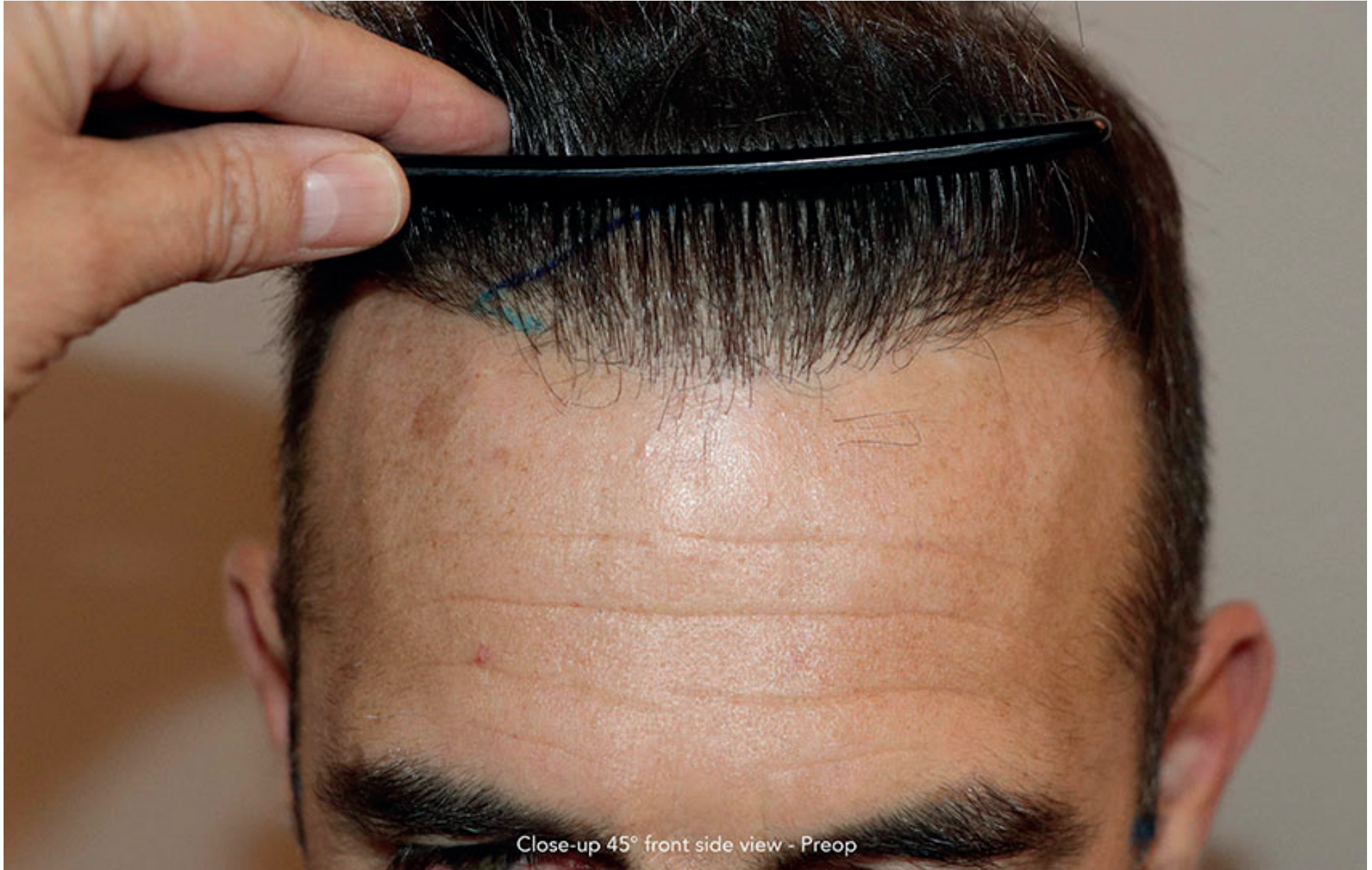Dr. Bijan Feriduni

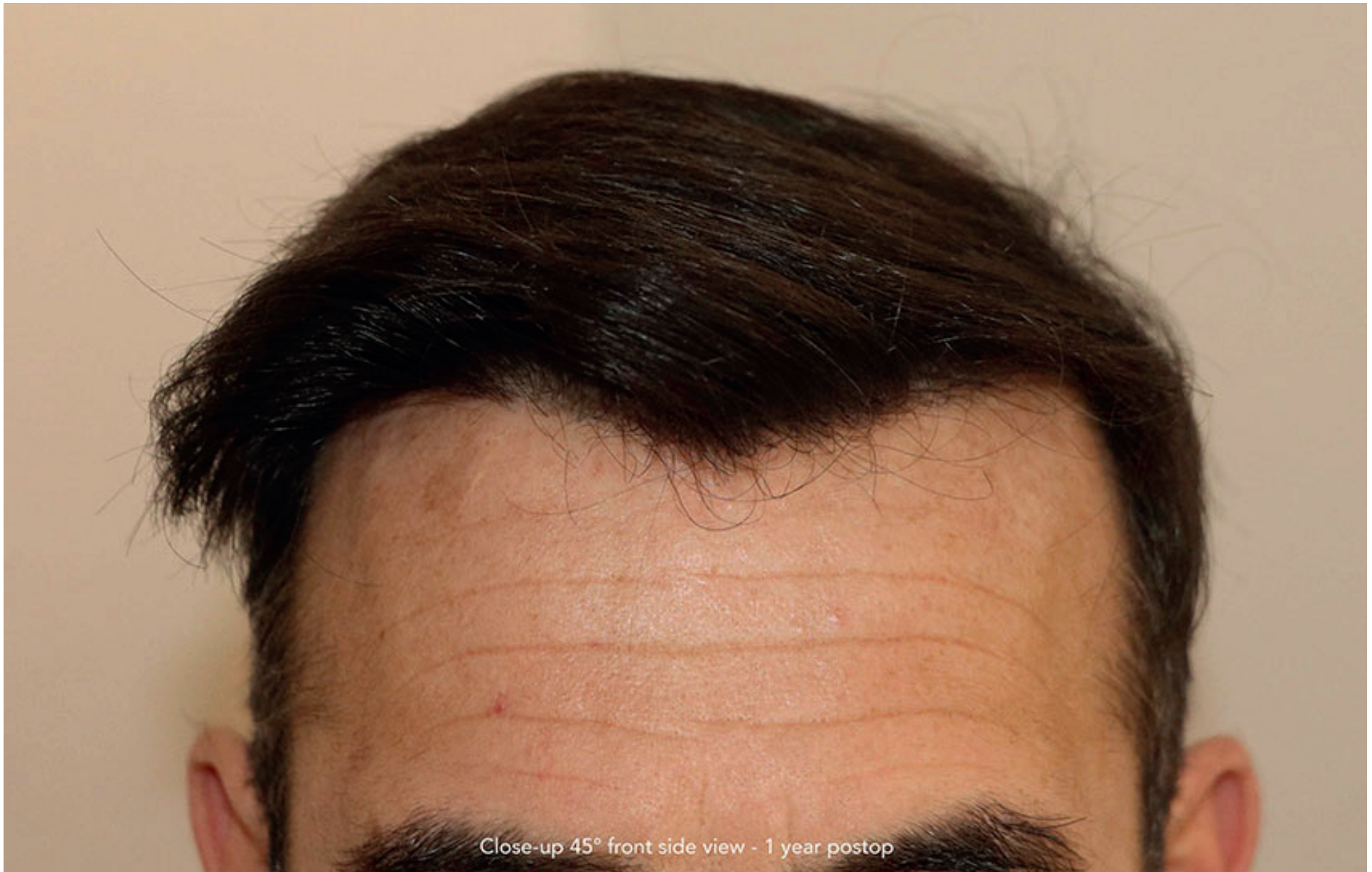

Preop



1 year postop

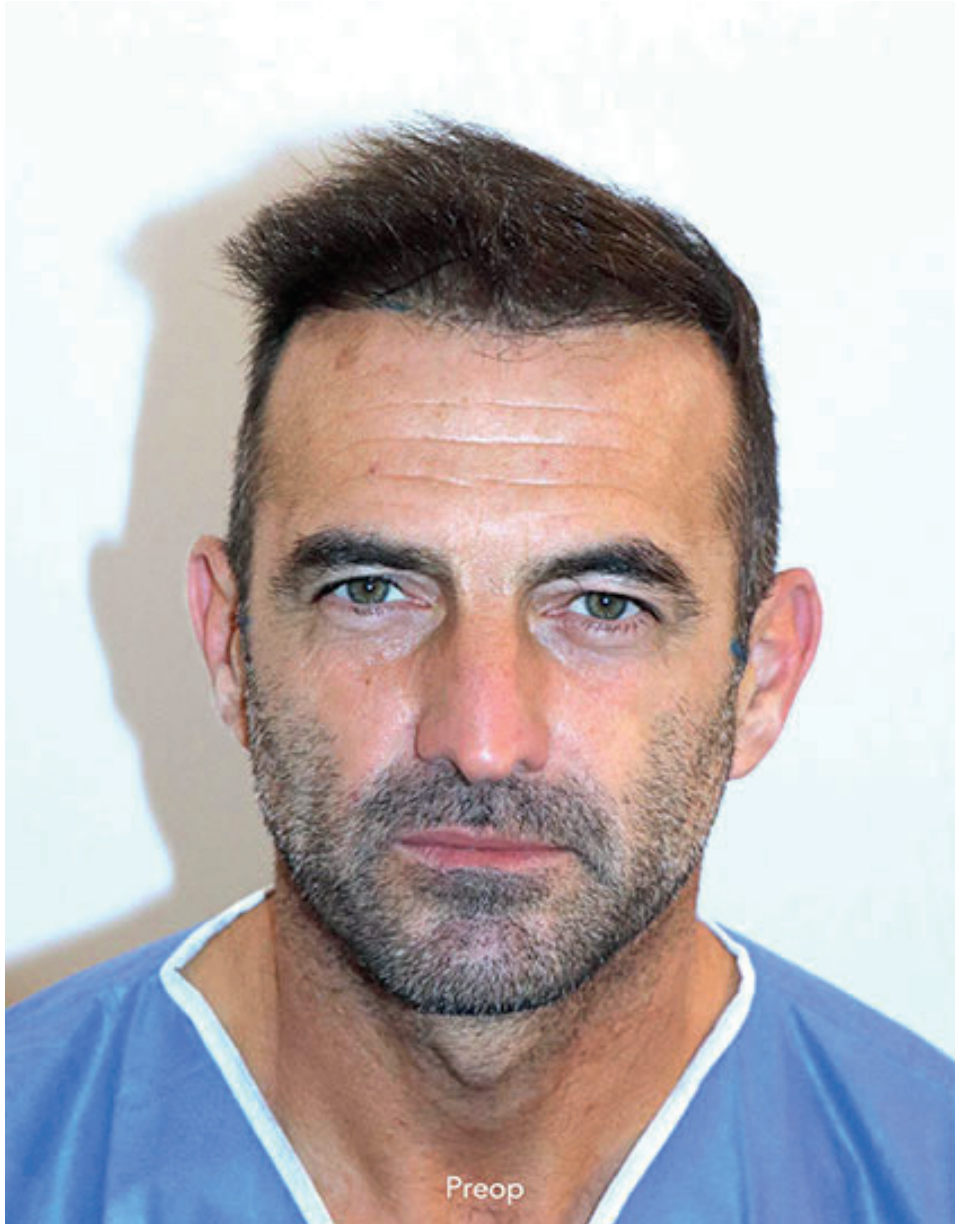



Close-up 45° front side view - 1 year postop



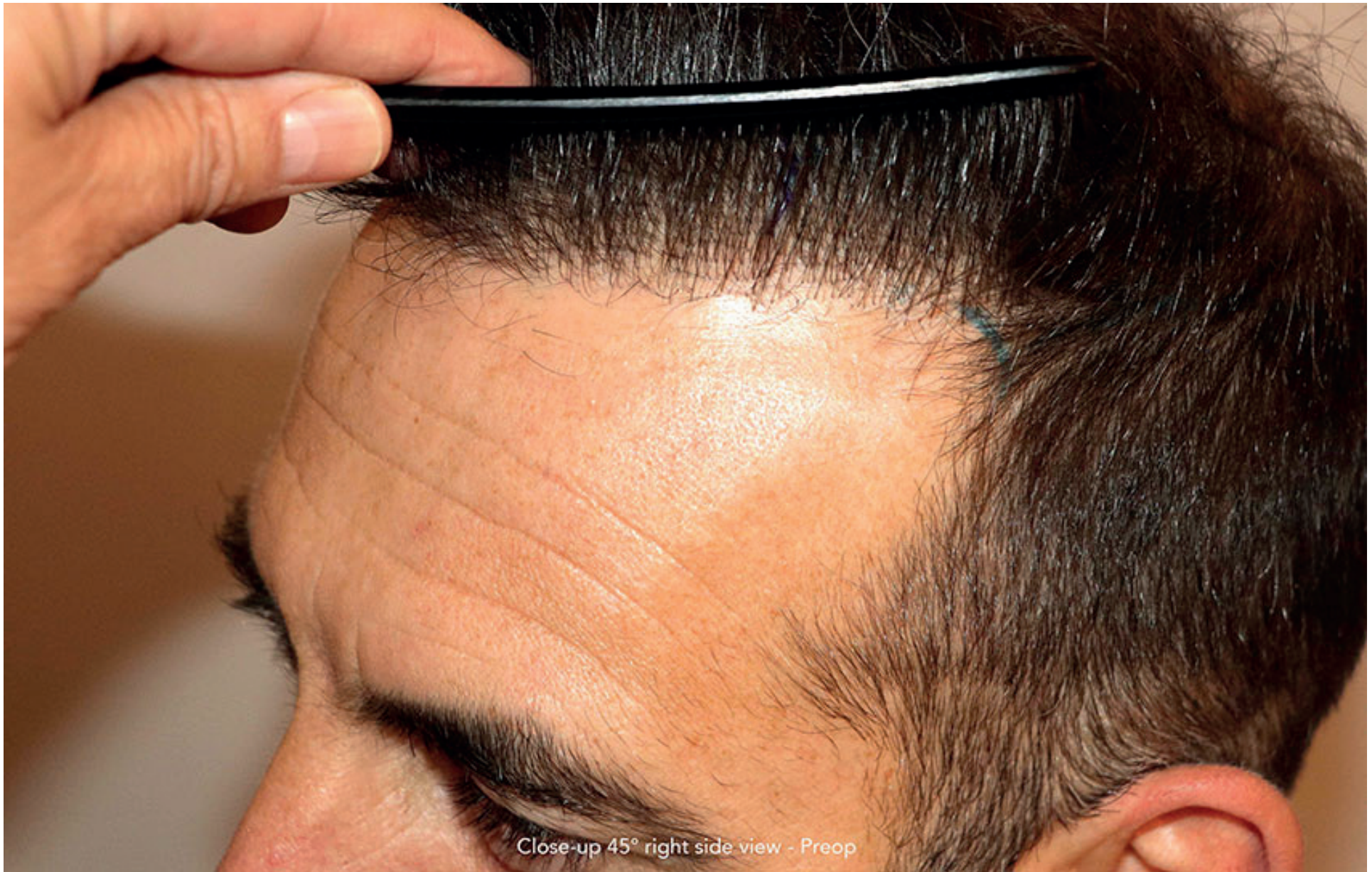DR. FERIDUNI
HAIR CLINIC



Preop



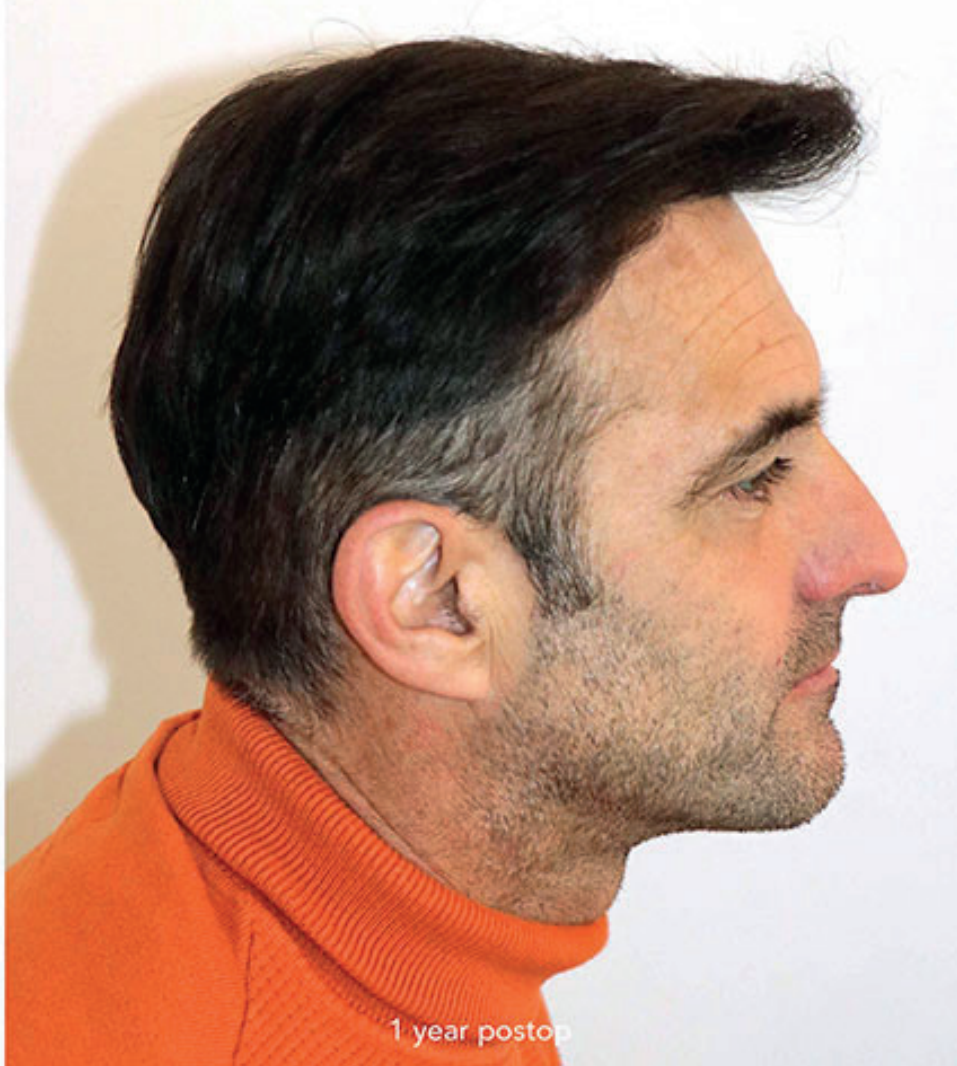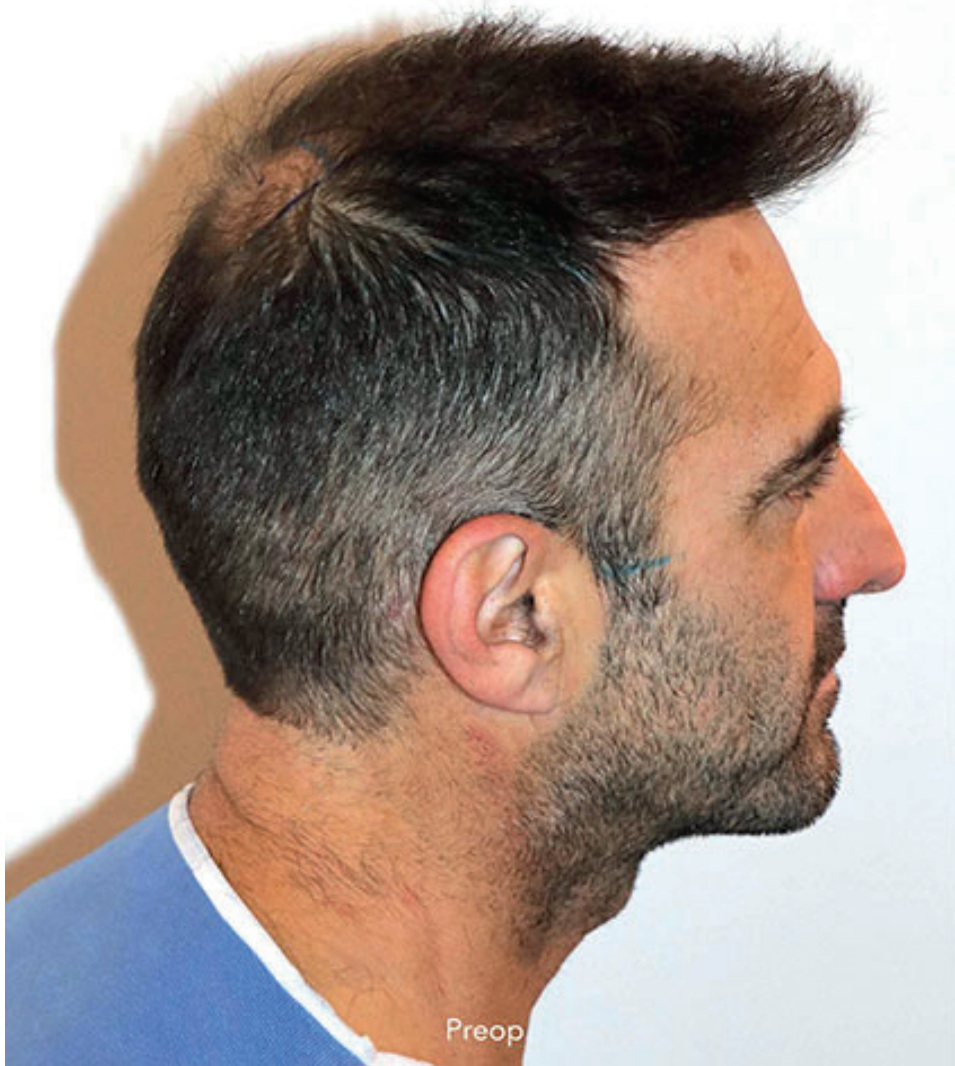1 year postop

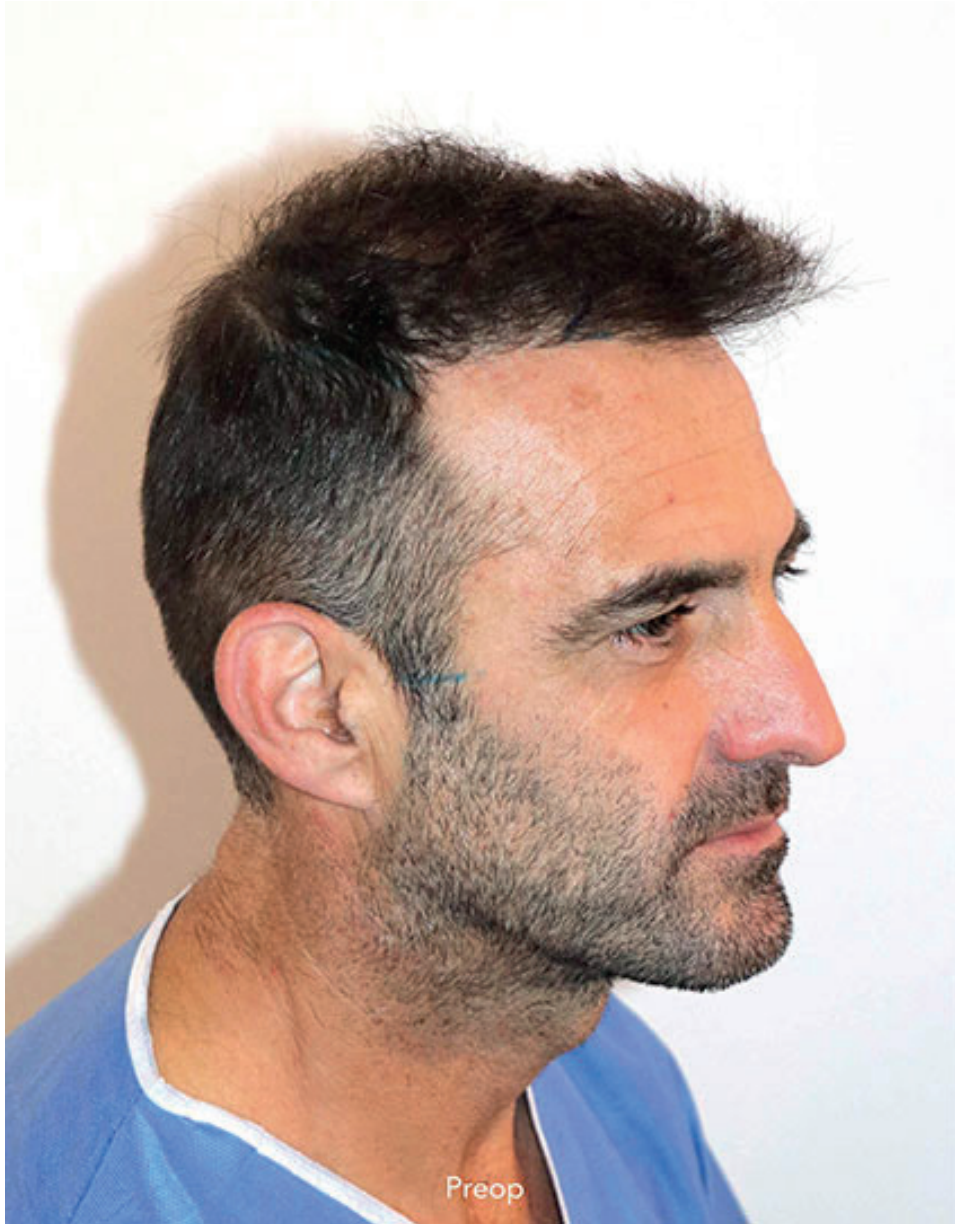

Close-up 45° right side view - Preop

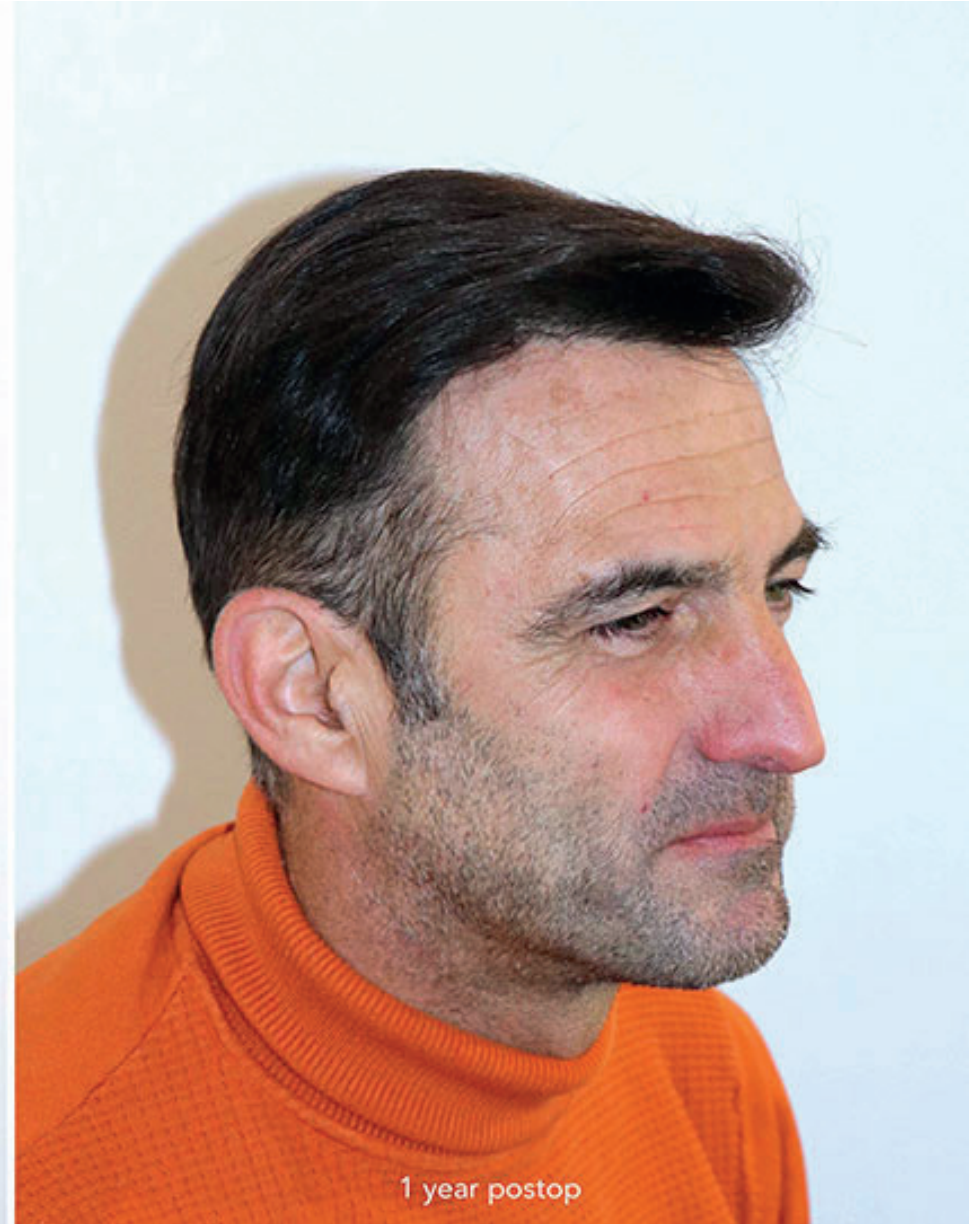

Close-up 45° right side view - 1 year postop





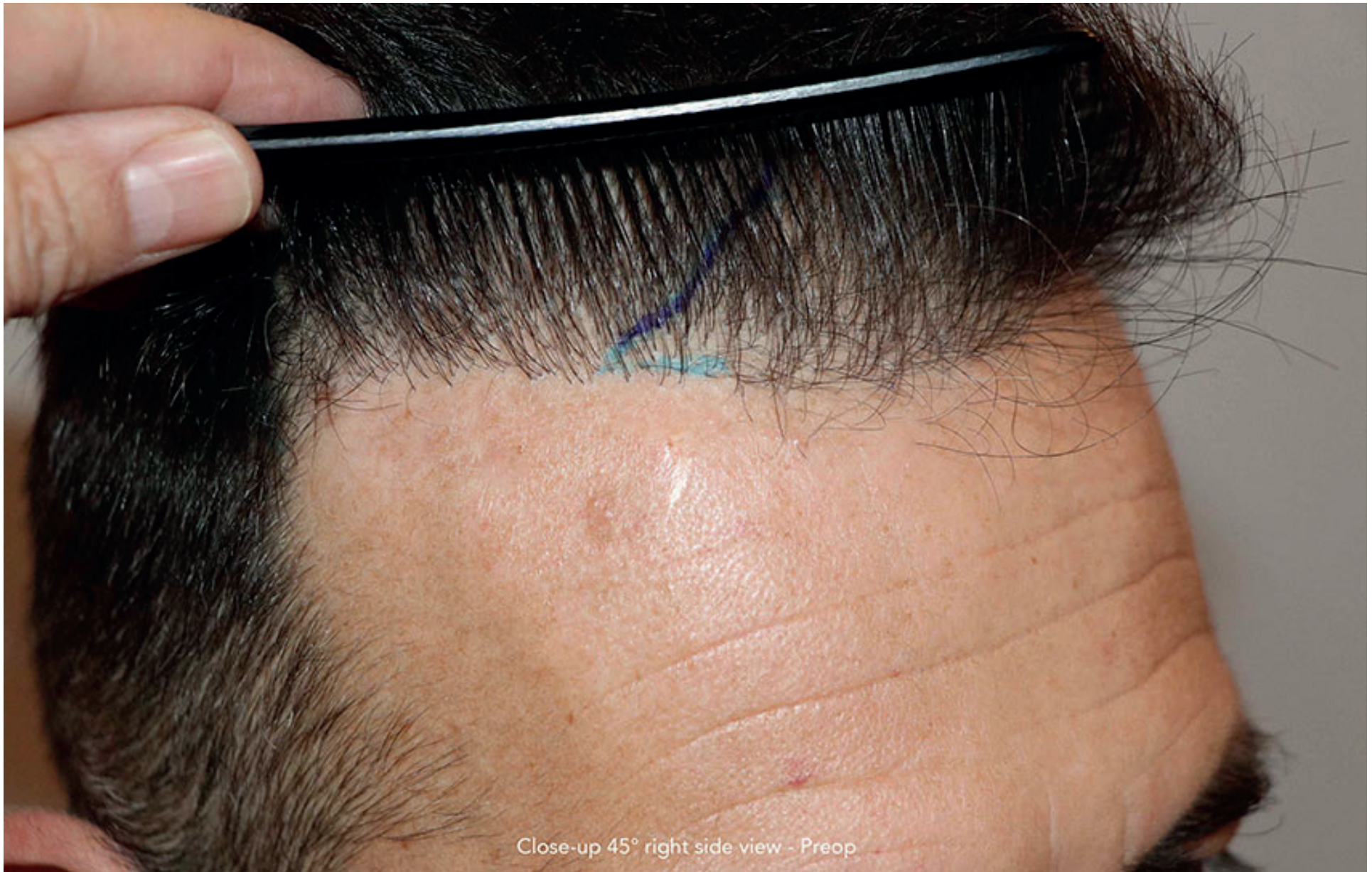Preop



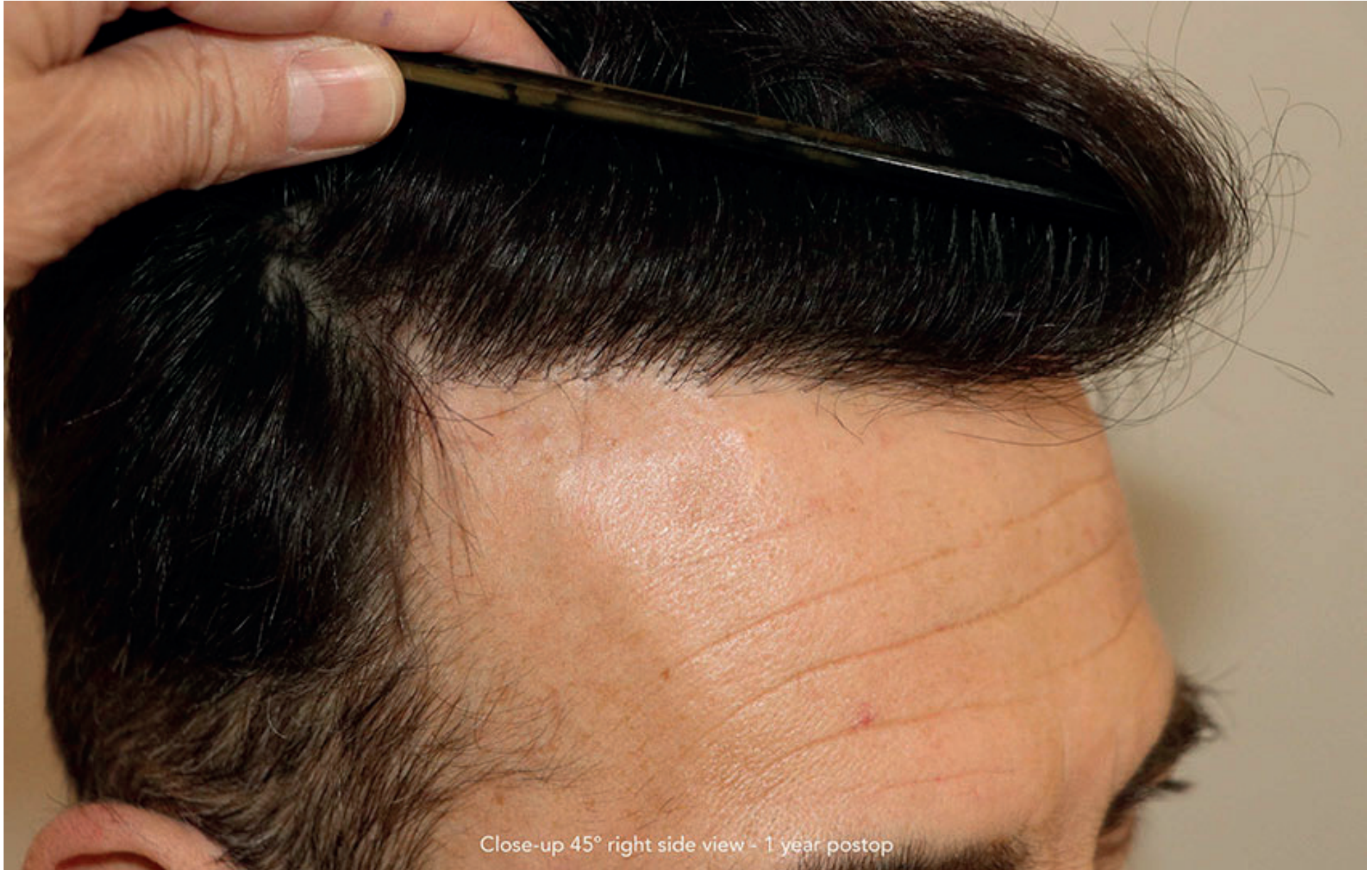1 year postop



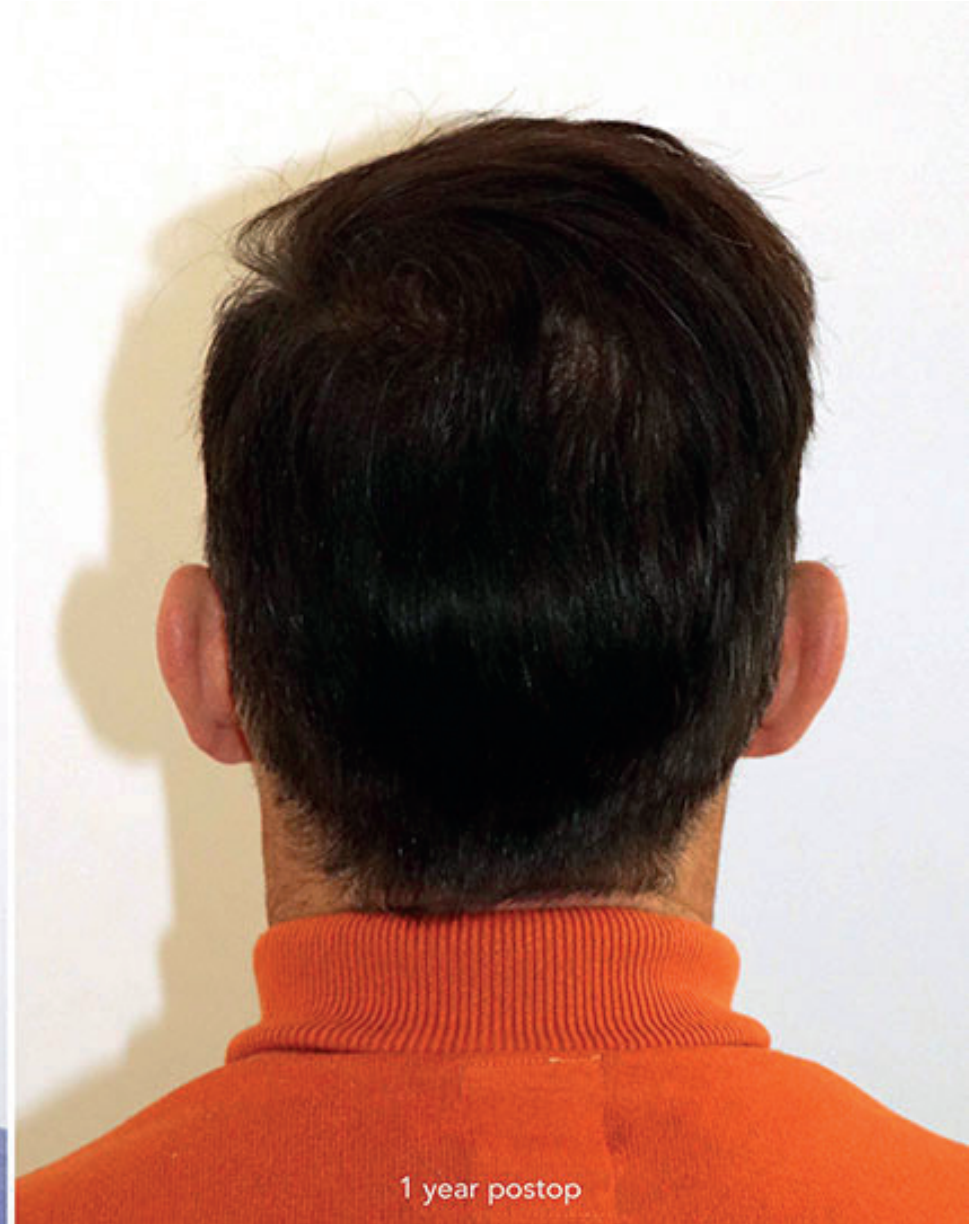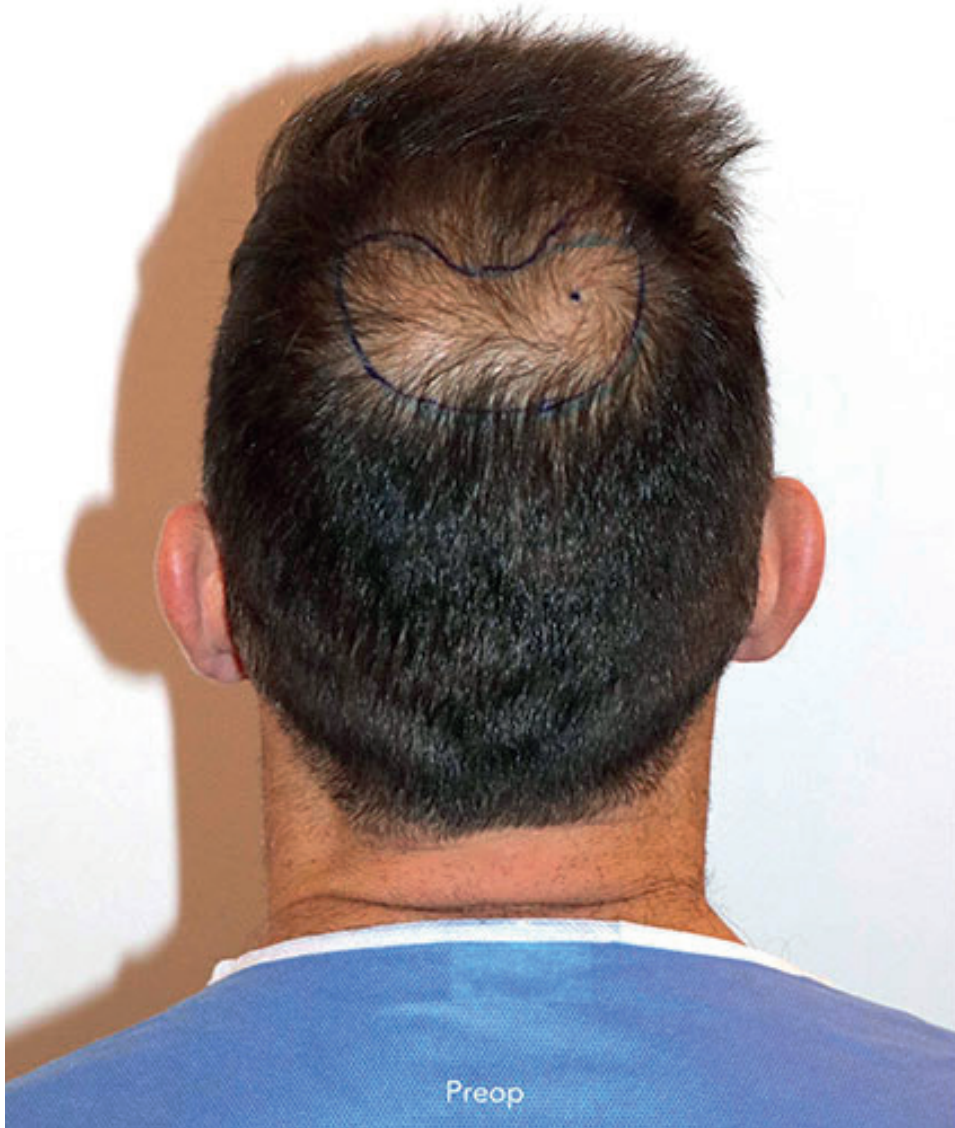DR. FERIDUNI
HAIR CLINIC

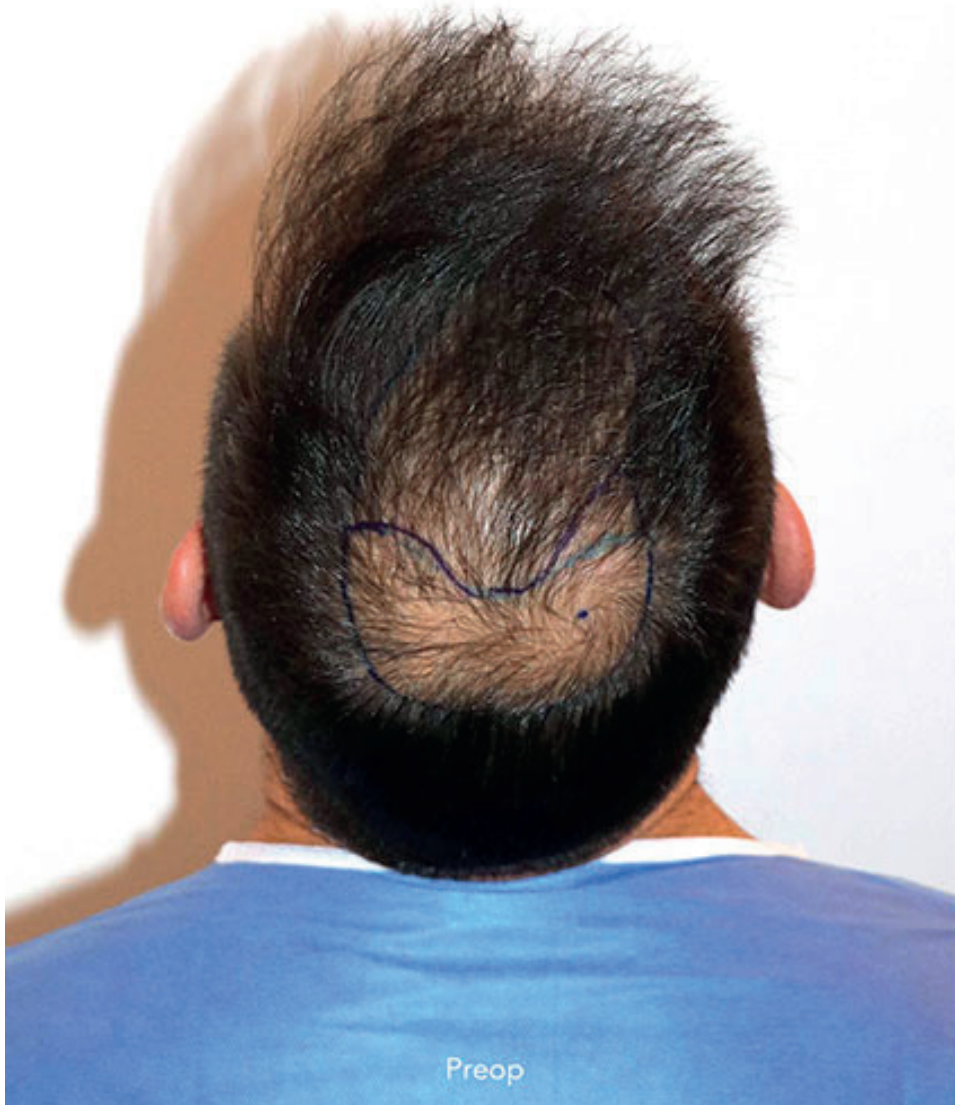

Close-up 45° right side view - Preop

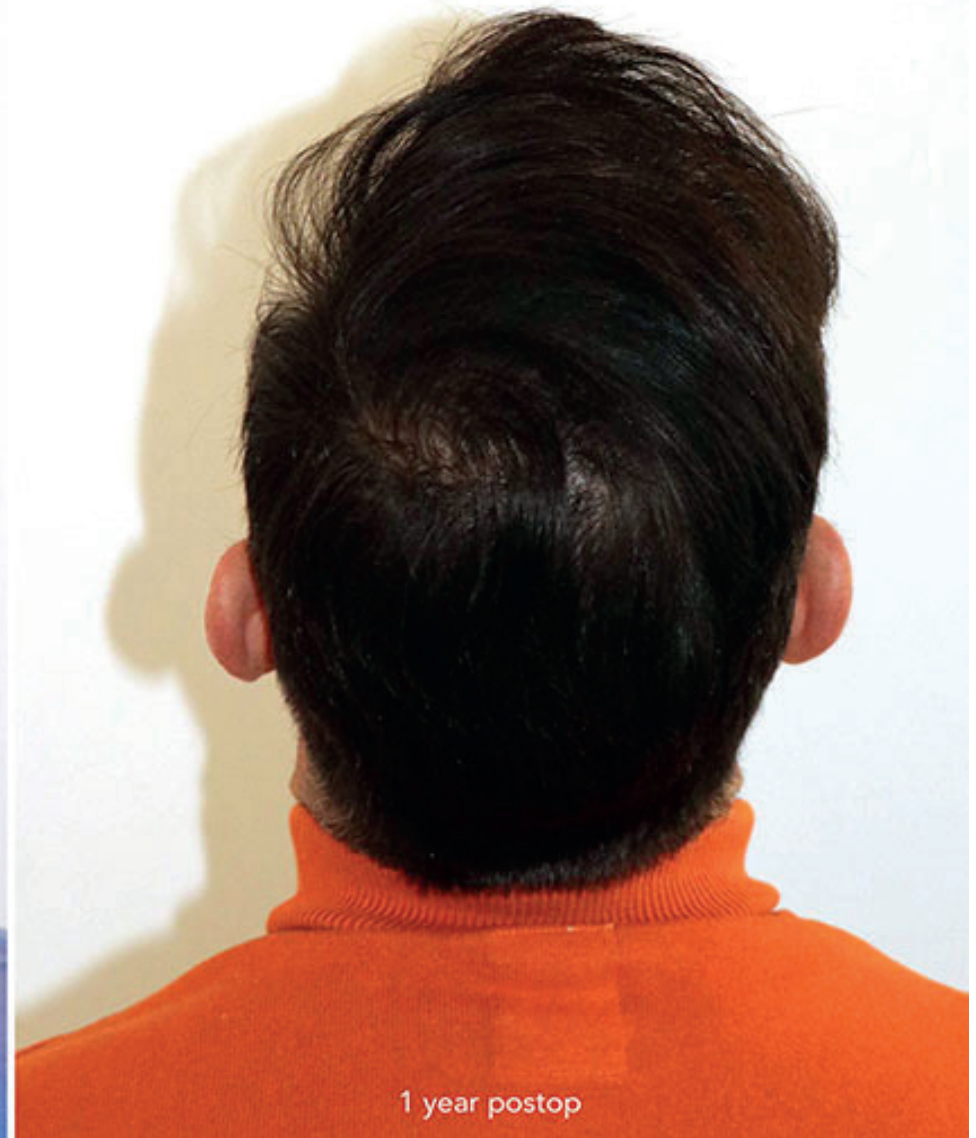


Close-up 45° right side view - 1 year postop

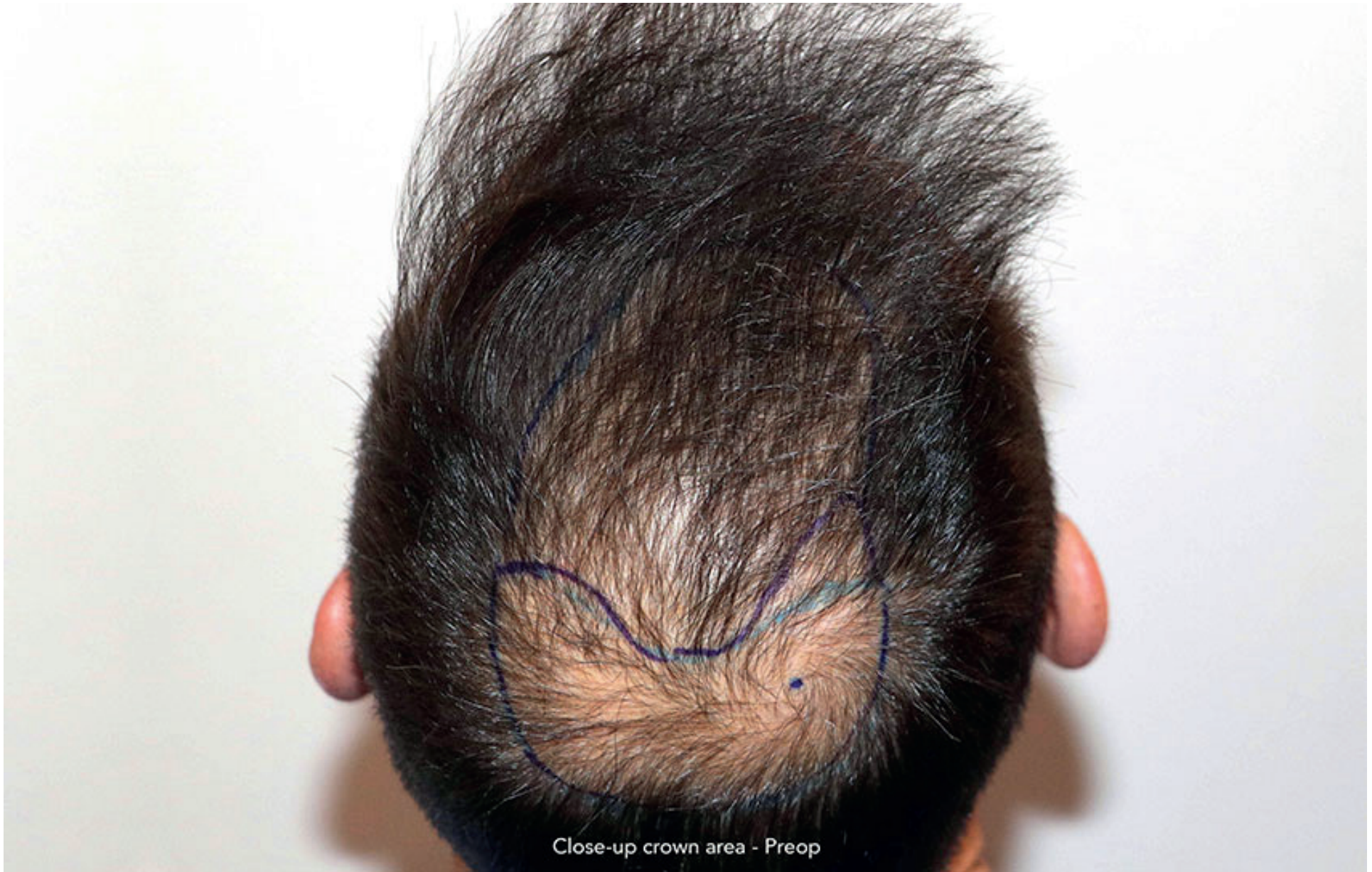



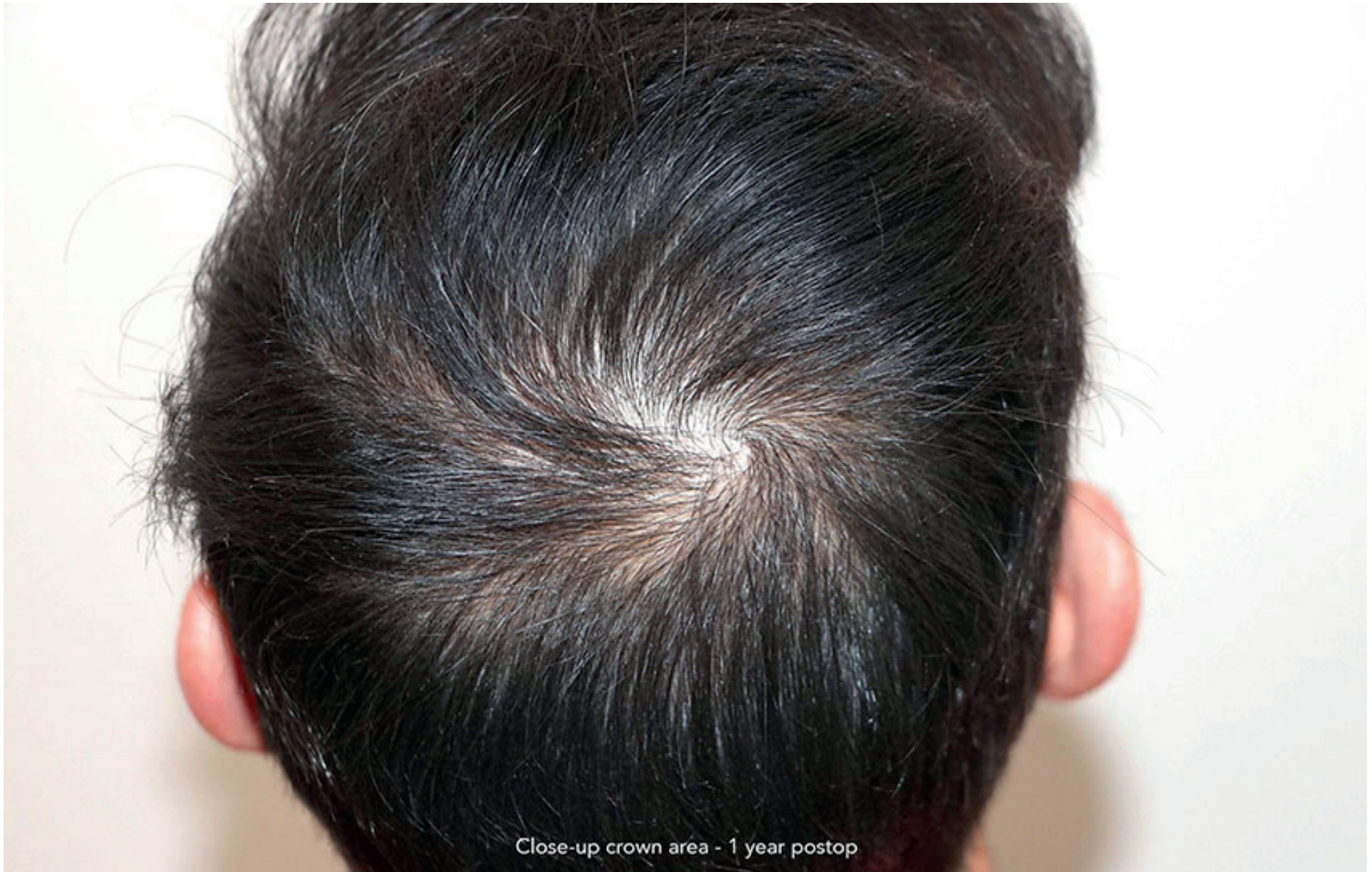
Preop



1 year postop



Close-up crown area - Preop



Close-up crown area - 1 year postop